

VULVAL DERMATITIS

PERIANAL ECZEMA (DERMATITIS)

Ill defined erythema with mild lichenification (thickening) in the perianal area.
Fissure visible at fourchette.

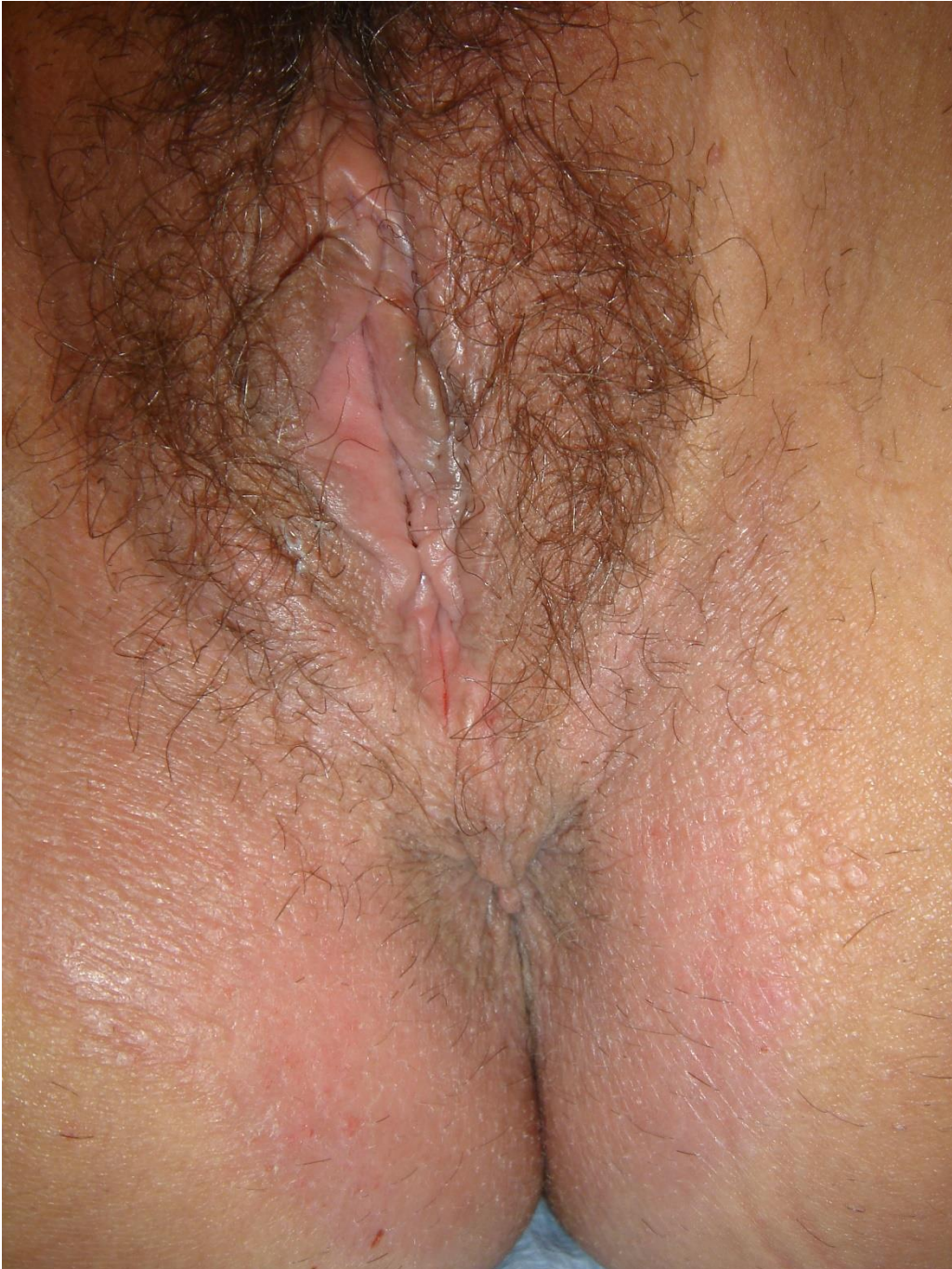


Image subject to copyright - reprinted with kind permission of the owner