

LICHEN SCLEROSUS 1

EXTRAGENITAL LICHEN SCLEROSUS

Axillary region showing a wide area of confluent porcelain-white papules and plaques with small areas of ecchymoses (bruising) at 5 o'clock.

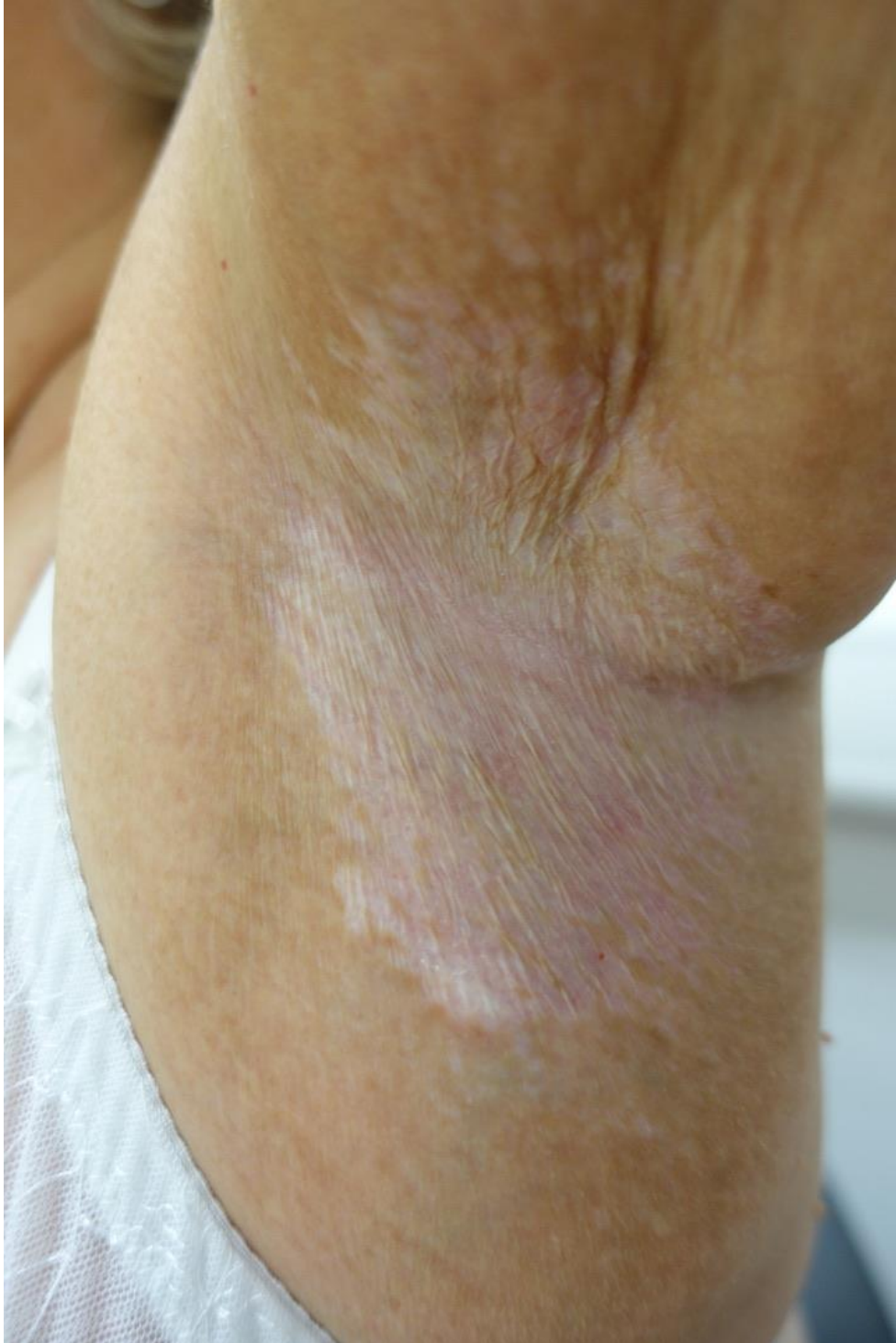


Image subject to copyright - reprinted with kind permission of the owner